

# Evidence of *Plasmodium falciparum* 12 years following the initial infection: A case report and mini-review of the literature

ANDREA MARINO<sup>1</sup>, MADDALENA CALVO<sup>2</sup>, GIUSEPPE MIGLIORISI<sup>2</sup>, EDOARDO CAMPANELLA<sup>3</sup>,  
ANTONINA FRANCO<sup>4</sup>, ELISA CAPPELLO<sup>4</sup>, LAURA TROVATO<sup>5</sup> and ILDEBRANDO PATAMIA<sup>2</sup>

<sup>1</sup>Unit of Infectious Diseases, Department of Clinical and Experimental Medicine, ARNAS Garibaldi Hospital, University of Catania; <sup>2</sup>U.O.C. Laboratory Analysis Unit, A.O.U. 'Policlinico-Vittorio Emanuele', I-95123 Catania;

<sup>3</sup>Unit of Infectious Diseases, Department of Clinical and Experimental Medicine, University of Messina, I-98124 Messina;

<sup>4</sup>Unit of Infectious Diseases, Umberto I Hospital, I-96100 Siracusa; <sup>5</sup>Department of Biomedical and Biotechnological Sciences, University of Catania, I-95123 Catania, Italy

Received July 15, 2023; Accepted October 30, 2023

DOI: 10.3892/wasj.2023.212

**Abstract.** *Plasmodium falciparum* (*P. falciparum*) malaria continues to pose a significant threat to public health worldwide, particularly in endemic areas. While the majority of cases can be effectively treated and cured, recurrences of *P. falciparum* malaria are not uncommon and can occur years following initial exposure. This phenomenon adds a new level of complexity to the management and prevention of the disease. The present study describes the compelling clinical case of a patient who contracted malaria despite not having been in an endemic region for over a decade. The patient had previously been infected and treated for the same disease. With low parasitemia, the patient was successfully treated with anti-malarial drugs; however, certain aspects of his medical history remained unclear. The present study also discusses the possibility that this case represents *P. falciparum* recrudescence or cryptic malaria, drawing on existing literature to contextualize the findings. The case presented herein highlights the need for continued vigilance in the diagnosis and treatment of *P. falciparum* malaria, particularly in instances of recurrence. Furthermore, it underscores the ongoing challenges posed by this persistent and insidious disease.

## Introduction

Malaria represents a significant global public health issue that affects a substantial percentage of the world's population, particularly those residing in tropical and subtropical regions. Despite the availability of effective antimalarial drugs and insecticides, individuals remain at risk, particularly in low-income countries where infection rates remain high. In Africa, for instance, these countries continue to record the highest incidence of infections. Several species of the parasite contribute to human infection, with similar life cycles, but varying abilities to persist in the human body with relapses or recrudescence (1). Relapses are episodes caused by *Plasmodium vivax* or *Plasmodium ovale*, whose symptoms and asexual stages appear months to years after the primary infection has cleared due to exoerythrocytic stages (hypnozoites). According to the World Health Organization (WHO) malaria terminology, a relapse is the recurrence of asexual parasitemia in *Plasmodium vivax* and *Plasmodium ovale* malaria that results from persisting liver stages (2). By contrast, recrudescence is the recurrence of asexual parasitemia of the same genotype(s) that caused the original illness following inadequate or ineffective antimalarial treatment (3). Recrudescence is therefore considered the result of the incomplete clearance of asexual stages of the parasite and has only been shown to occur with *Plasmodium malariae* and *Plasmodium falciparum* (*P. falciparum*) (4). Among the plasmodia, *P. falciparum* is the most dangerous due to its association with severe clinical complications, and high morbidity and mortality rates (1). The duration of *P. falciparum* infections cannot be accurately determined and has been controversial since the first health policy on eradication was applied in the 1950s. Although these infections typically last no longer than 1 year, some case reports (please see Table I) have documented suspected recrudescence episodes within one to 13 years following primary infection parasite clearance (5). *P. falciparum* recrudescence may be caused by incomplete anti-malarial treatment (6).

---

**Correspondence to:** Dr Maddalena Calvo, U.O.C. Laboratory Analysis Unit, A.O.U. 'Policlinico-Vittorio Emanuele' Via S. Sofia 78, I-95123 Catania, Italy  
E-mail: maddalenacalvo@gmail.com

**Abbreviations:** ANA, antinuclear antibody; ENA, extractable nuclear antigen; FUO, fever of unknown origin; HIV, human immunodeficiency virus

**Key words:** malaria, *Plasmodium falciparum*, cryptic malaria, malaria recrudescence

The present study describes the case of a young male patient with potential *P. falciparum* recrudescence who experienced symptoms 12 years after his last exposure to the *Plasmodium* genus parasite.

### Case report

A 32-year-old male patient from Chad presented at the Umberto I Hospital (Siracusa, Southern Italy) Emergency Department with a fever of up to 38.5°C, chills, and general discomfort. He had moved to Italy in 2009 and had not returned to his home country since. Furthermore, he did not document any travels to other malarial endemic countries. The patient reported a not otherwise specified anti-malarial treatment for a microscopically diagnosed episode of *P. falciparum* malaria (2005) in a non-specified hospital in Chad and was monitored for suspected mixed connective tissue disease. He denied exposure to or contact with individuals from malaria-endemic areas, travel or stay in airports, as well as other risk factors, such as blood transfusions, organ transplantations, or intravenous drug use. Moreover, the patient documented that his residential city neighborhood was in a non-endemic area for malaria (7) and far from airports. He confirmed the absence of any professional risk factors, noticing his profession (warehouse worker in a shopping center). Upon his admission (May 1, 2021), he was febrile (temperature, 38°C), his blood pressure was 140/70 mmHg, his heart rate was 110 bpm, his oxygen saturation in room air was 96% and his respiratory rate was 20 breaths/min. The Glasgow Coma Scale was 15 (indicating that he was fully awake, responsive and with no issues in cognitive ability or memory). A physical examination revealed mild abdominal pain and bilateral crackling breath sounds. A chest X-ray and subsequent thorax computed tomography (CT) scan documented pulmonary microembolism (Fig. 1), while an abdomen CT scan revealed hepatomegaly and mesenteric lymphadenopathy (these images are not available). Laboratory data revealed mild anemia (hemoglobin, 10.6 g/dl; normal values, 14–16.5 g/dl) with a reduced red blood cell count ( $3.55 \times 10^6/\text{mm}^3$ ; normal values,  $4.52\text{--}5.90 \times 10^6/\text{mm}^3$ ); his white blood cell count was  $11,100/\text{mm}^3$  (normal values,  $4,000\text{--}11,000/\text{mm}^3$ ) with monocytosis ( $1,500/\text{mm}^3$ ); his platelet count was  $100,000/\text{mm}^3$  (normal values,  $150,000\text{--}400,000/\text{mm}^3$ ); the levels of inflammatory markers were elevated: C-reactive protein, 111 mg/l (normal values 0–5 mg/l); erythrocyte sedimentation rate, 100 mm/h (normal values, <20 mm/h); procalcitonin level, 2 mcg/l (normal values, <0.1 mcg/l); and D-dimer level, 4,000 ng/ml (normal values, <500 ng/ml). The levels of transaminases (glutamic oxaloacetic transaminase, 38 U/l; glutamic pyruvic transaminase, 40 U/l; normal values, <45 U/l) and bilirubin (1 mg/dl; normal values, <1.8 mg/dl) were normal, as well as those of coagulation parameters (international normalized ratios 0.9; normal values, <1.2). His creatinine level was 0.9 mg/dl with an estimated glomerular filtration rate of 131 ml/min. The patient also presented with high ferritin levels (1,000 ng/ml). Glucose levels were normal (88 mg/dl; normal values, <100 mg/dl). The patient tested negative for human immunodeficiency virus (HIV), hepatitis B and C virus, as well as Epstein-Barr virus, *Toxoplasma* and cytomegalovirus. Further tests for *Brucella*, *Salmonella* and

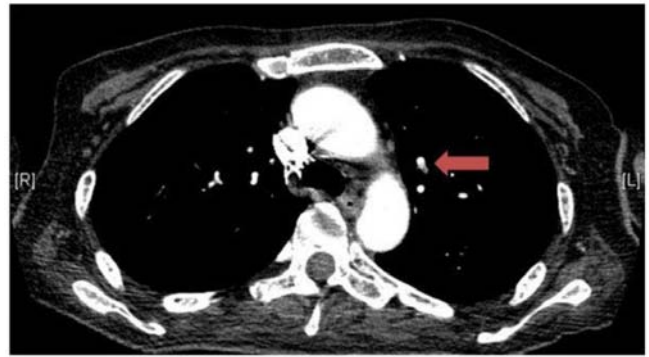

Figure 1. Thoracic computed tomography scan of the patient demonstrating a pulmonary microembolism (red arrow).

*Treponema pallidum* were negative. The autoimmune panel revealed positive results for antinuclear antibody (ANA) and extractable nuclear antigen (ENA) 1:160. Empiric antibiotic therapy with intravenous ceftriaxone was administered along with anticoagulant treatment based on enoxaparin. Given the patient's origin, it was deemed appropriate to investigate the persistence of malaria. A rapid diagnostic test for malaria (Bioline™ Malaria Ag P.f., Abbott Pharmaceutical Co. Ltd.) yielded positive results for pan-malarial aldolase antigen and *P. falciparum* histidine-rich protein 2. Subsequently, microscopical examinations were performed. The microscopical assay required a 2.5% Giemsa stain (Kaltex S.r.l.) for the thick film, while the thin film was performed using a 10% Giemsa stain (Kaltex S.r.l.). Buffered water (pH 7.2–7.3) was used to remove unnecessary stain drops after the first coloration steps. Both the Giemsa stain and the buffered water were stored at 25°C before their application within the diagnostic protocol. The microscopic examination of the thick film confirmed the presence of a *Plasmodium* genus parasite with a parasitemia of 4.0 asexual parasites/ $\mu\text{l}$ . Specifically, a total number of 200 leukocytes were counted within 200 microscopic fields.

The thin smear (Fig. 2) revealed ring-shaped trophozoites, normal-sized erythrocytes and rare banana-shaped gametocytes. *P. falciparum* malaria was diagnosed. This result was confirmed by two further tests, performed at 8 and 12 h following the first test and the beginning of anti-malarial treatment. Specifically, anti-malarial treatment with piperaquine/dihydroartemisinin at 300/40 mg/day for 3 days was administered. After 24 h, malaria parasitemia was re-evaluated revealing only the presence of *P. falciparum* banana-shaped gametocytes (Fig. 3). The fever disappeared together with clinical improvement and normalization of inflammatory markers. At 48 h following the initiation of anti-malarial therapy, a new blood sample was taken resulting in a completely negativity for malaria infection. Within 10 days, the patient appeared to be clinically recovered and was discharged. At 2 weeks after discharge, thoracic and abdominal CT scans (images are not available) revealed no clinical abnormalities, indicating the complete resolution of the previous pulmonary microembolism. Laboratory tests documented a complete recovery. The patient was then referred by the rheumatology specialist due to the suspicion of mixed connective tissue disease (as suggested by ANA and ENA).

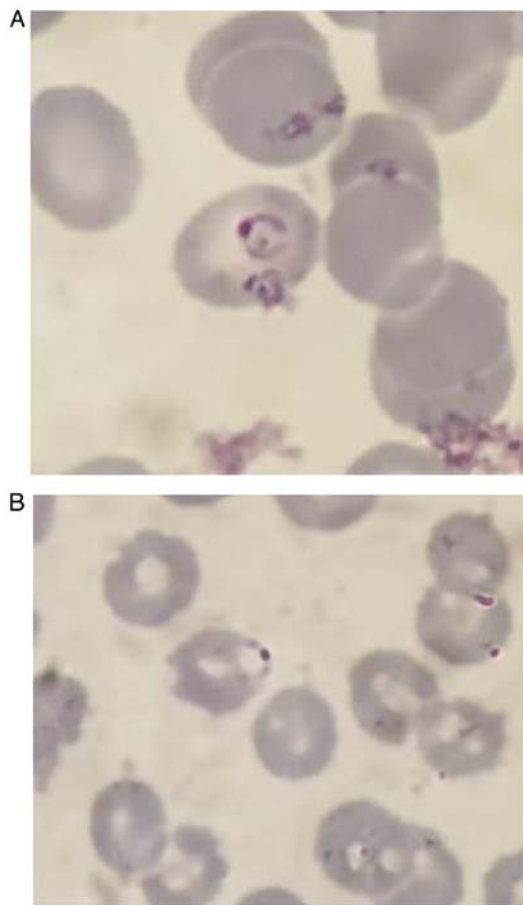


Figure 2. Thin smear microscopic examination showing *Plasmodium falciparum* trophozoites. (A and B) Sections illustrating the presence of ring-shaped *Plasmodium falciparum* trophozoites. All the microscopic fields were observed through a x100 oil immersion magnification.

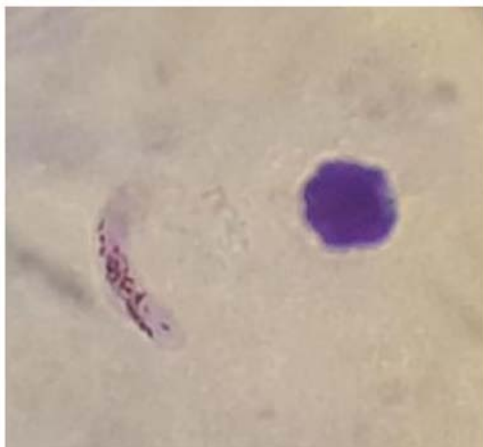


Figure 3. Thin smear microscopic examination illustrating a banana-shaped *Plasmodium falciparum* gametocyte through x100 oil immersion magnification.

## Discussion

Malaria is currently one of the most significant global threats, and numerous international studies have been conducted to highlight the challenging spread and evolution of this infectious disease (8). *Plasmodium* species that infect humans

follow a similar multistage life cycle, characterized mainly by two stages: An initial liver stage followed by proliferation in the blood (1). The clinical impact of malaria varies among different species, with *P. falciparum* being considered the most dangerous due to its ability to cause severe complications, such as cerebral malaria and critical sequelae, resulting in high morbidity and mortality rates in both adult and pediatric patients. Additionally, *Plasmodium* species may differ in their persistence modes (1).

It has been documented that *P. falciparum* can cause recrudescence, even a decade after the last exposure, despite not having the ability to produce hypnozoites. Inadequate or incomplete anti-malarial treatment is the main risk factor for recrudescence. Incomplete anti-malarial treatment hinders the clearance of parasites and modulates parasitemia. According to several studies, 32 cases of *P. falciparum* malaria were diagnosed in patients who had left an endemic area 7 months to 15 years prior (9-13). Of these cases, three were solely related to *P. falciparum* gametocytaemia observed on blood films.

According to the literature (9-14), these reports suggested that some patients were able to easily clear the infection themselves. Out of the 32 cases reported, 5 patients had taken anti-malarial medication in the previous months, while 13 cases were associated with comorbidities, pregnancy, or trauma. A summary of the cases of *P. falciparum* malaria mentioned above, occurring months or years after the last exposure is presented in Table I.

Based on the patient's medical history, it appears that a previous malarial episode was not properly treated due to incomplete intake or ineffectiveness of the prescribed anti-malarial treatment. It is reasonable to assume that the patient's current infection was caused by *P. falciparum*, which was the predominant species in Chad between 2005 and 2010 (2-4,15). Other potential risk factors such as diabetes, HIV infection, anemia, and head injury have been ruled out. Therefore, physical stress and incomplete antimalarial treatment are the only factors that could be related to the patient's current condition.

The scientific literature on *P. falciparum* has provided evidence of subclinical infections that can keep patients at risk of developing recrudescence and becoming a reservoir for malaria mosquitoes. When there is suspicion of a recrudescence episode, specific attention is required in the malaria diagnostic process (16). Moreover, data confirm the importance of monitoring countries that have achieved malaria elimination carefully. Patients with asymptomatic infections can represent a silent reservoir for the survival of the parasite in some countries. Therefore, it is recommended to perform supervision for 3 years after declaring malaria elimination in a previous malaria-endemic country (9).

The *P. falciparum* parasites constantly affect the human immune system through various mechanisms to gain benefits for their survival (17). Scientific data have also suggested an association between the persistence of *P. falciparum* and the presence of antigenic variants of the parasite (18). *P. falciparum* attempts an immune escape strategy by producing antigenic variants different from the original infectious strain. These variants have differential expression levels of *var* genes that encode PfEMP1 proteins. Although some variants may evade the immune response, they are less able to bind receptors and form erythrocytic adhesions. It may be hypothesized

Table I. Summary of *Plasmodium falciparum* malaria cases identified in the literature which occurred after several months or years after the last exposure.

First author	Time since last exposure	Patients' risk factors	Microscopic evidence	(Refs.)
Nagley	13-17 years	Inadequate antimalarial treatment during previous infections	Trophozoites and gametocytes	(24)
Walters	19 months	Pregnancy	Trophozoites	(25)
Russell	4 years	Unclear	Trophozoites	(26)
Revel	3 years	HIV infection; pregnancy	Trophozoites and gametocytes	(27)
Kyrönseppä	20 months	Head injury	Trophozoites	(10)
Krajden	32 months	Diabetes	Trophozoites	(11)
Shah	15 years	Unclear	Trophozoites	(28)
Giobbia	4 years	Pregnancy	Trophozoites	(12)
Howden	9 years	Previous history of abdominal surgery	Trophozoites	(29)
Greenwood	4 years	Sickle cell disease	Trophozoites	(13)
D'Ortenzio	7 months (1 case); 1 year (5 cases); 9 years (5 cases).	HIV infection (5 cases); pregnancy (5 cases); unclear (1 case).	Trophozoites	(30)
Theunissen	9 years	Unclear	Trophozoites	(14)
Foca	11 months	Cancer	Gametocytes	(31)
Szmitko	8 years	Unclear	Trophozoites	(32)
Mali	2 years (1 case); 3 (1 case); 4 years (1 case).	Unclear	Trophozoites	(33)
Cullen	3 years	Unclear	Trophozoites	(34)
Monge-Maillo	13 months (1 case); 14 months (1 case); 28 months (1 case)	Unclear	Trophozoites	(35)
Berrevoets	2.5 years	Unclear	Trophozoites and schizonts	(36)

that less virulent antigenic variants can persist post-clearance with minimal or no clinical manifestations. It is reasonable to assume that some variants reduce their fitness to allow long-term persistence in the human host (18). This could provide a basis for further studies, as ideally, less virulent *P. falciparum* variants should be investigated in every doubtful case of malaria (19).

Some cases of suspected *P. falciparum* recrudescence can be categorized as cryptic malaria. This term is defined by the Centers for Disease Control and Prevention (CDC) as 'a case of malaria where epidemiologic investigations fail to identify an apparent mode of acquisition (this term applies mainly to cases found in non-endemic countries)' (20). Cryptic malaria can occur when there is an unreliable patient travel history, diagnostic delays, suspected importation of an infected mosquito, or transmission through contact with infected blood or tissue (3,21).

However, in the case described in the present study, risky conditions such as transfusions, transplantations, intravenous drug intake, airport proximity, travel and contact with individuals from endemic areas were ruled out by the patient. The objective was to investigate a doubtful case where the origin is uncertain and to determine whether it is a case of cryptic malaria or a recrudescence of *P. falciparum*.

To achieve this goal, the patient's epidemiological and clinical history was examined. He had left Chad, an endemic region for malaria, 12 years prior, and was currently presenting with high procalcitonin and parasitemia with *P. falciparum*. It is well known that procalcitonin levels can be elevated during malaria, particularly when there is a long interval between the first symptoms and the diagnosis (22). Thus, the high procalcitonin values of the patient described herein, without any signs of sepsis supported the suspicion of malaria infection. Furthermore, it was suspected that the patient may have experienced transient immunodepression due to a stressful life situation (a business trip) and a suspected mixed connective tissue disease.

A positive blood culture several days following a diagnosis of malaria never developed into overt sepsis, and no further positive tests followed. Therefore, it was concluded that the high procalcitonin level may be related to the malaria episode rather than bacteremia. The patient firmly denied all possible predisposing factors for cryptic malaria. As a result, the authors are confident that this may be one of the rare cases of *P. falciparum* recrudescence with low parasitemia, 12 years after the patient's last exposure. In summary, the predisposition to believe in a *P. falciparum* recrudescence could be supported by previous literature data about insufficient antimalarial treatment and parasite recrudescence after years.



In conclusion, the case presented herein underscores the importance of screening for malaria when faced with fever of unknown origin (FUO). Moreover, it highlights the need to consider malaria persistence as a potential diagnosis in certain patients. Fortunately, blood sampling and malaria diagnostics are simple and cost-effective procedures that can yield invaluable information without breaking the bank. Notably, the current guidelines from the Infectious Diseases Society of America (IDSA) recommend a physical examination, imaging tests and laboratory analyses, such as surveillance and blood cultures for the management of FUO (23). It is suggested that this algorithm be augmented with routine blood sampling for malaria diagnosis. Given the diverse mechanisms through which malaria can be transmitted, not all of which are easily recognizable, it is crucial to include this test in the workup of all FUO cases. This protocol expansion is necessary to ensure prompt and accurate diagnosis, and ultimately, improved patient outcomes.

### Acknowledgements

Not applicable.

### Funding

No funding was received.

### Availability of data and materials

Data sharing is not applicable to this article as no datasets were generated or analyzed during the current study.

### Authors' contributions

All authors (AM, MC, GM, EdC, AF, EIC, LT and IP) contributed to the study conception and design.

GM was involved in the study methodology. AF and EC were involved in examining the patient and the patient's data. LT was involved in data curation. AM and MC were involved in the writing and preparation of the original draft. IP was involved in the writing, review and editing of the manuscript and supervised the study. All authors have read and approved, and have agreed to the published version of the final manuscript. LT and IP confirm the authenticity of all the raw data.

### Ethics approval and consent to participate

Written informed consent was obtained from the patient for the inclusion of his data in the present study.

### Patient consent for publication

Written informed consent was obtained from the patient for the publication his data and any related images.

### Competing interests

The authors declare that they have no competing interests.

### References

1. Sato S: Plasmodium-a brief introduction to the parasites causing human malaria and their basic biology. *J Physiol Anthropol* 40: 1, 2021.
2. World Health Organization: WHO Malaria terminology, 2021 update. <https://www.who.int/publications/i/item/9789240038400>. Accessed September 10, 2023.
3. Malvy D, Torrentino-Madamet M, L'Ollivier C, Receveur MC, Jeddi F, Delhaes L, Piarroux R, Millet P and Pradines B: *Plasmodium falciparum* Recrudescence two years after treatment of an uncomplicated infection without return to an area where malaria is endemic. *Antimicrob Agents Chemother* 62: e01892-17, 2018.
4. World Health Organization: Guidelines for the Treatment of malaria, Third edition, 2015. <https://www.afro.who.int/publications/guidelines-treatment-malaria-third-edition>. Accessed September 10, 2023.
5. Buck E and Finnigan NA: Malaria. 2023. In: StatPearls (Internet). Treasure Island (FL), StatPearls Publishing, 2023.
6. Zekar L and Sharman T: *Plasmodium falciparum* malaria. In: StatPearls (Internet). Treasure Island (FL), StatPearls Pub-Lishing, 2021.
7. World Health Organization: World malaria report 2022. <https://www.who.int/teams/global-malaria-programme/reports/world-malaria-report-2022>. Accessed September 10, 2023.
8. Saydam FN, Erdem H, Ankarali H, El-Arab Ramadan ME, El-Sayed NM, Civljak R, Pshenichnaya N, Moroti RV, Mahmudabad FM, Maduka AV, *et al*: Vector-borne and zoonotic infections and their relationships with regional and socioeconomic statuses: An ID-IRI survey in 24 countries of Europe, Africa and Asia. *Travel Med Infect Dis* 44: 102174, 2021.
9. Ashley EA and White NJ: The duration of *Plasmodium falciparum* infections. *Malar J* 13: 500, 2014.
10. Kyrönseppä H, Tiula E, Repo H and Lähdevirta J: Diagnosis of falciparum malaria delayed by long incubation period and mis-leading presenting symptoms: Life-saving role of manual leucocyte differential count. *Scand J Infect Dis* 21: 117-118, 1989.
11. Krajden SP, Panisko DM, Tobe B, Yang J and Keystone JS: Prolonged infection with *Plasmodium falciparum* in a semi-immune patient. *Trans R Soc Trop Med Hyg* 85: 731-732, 1991.
12. Giobbia M, Tonon E, Zanatta A, Cesaris L, Vaglia A and Bisoffi Z: Late recrudescence of *Plasmodium falciparum* malaria in a pregnant woman: A case report. *Int J Infect Dis* 9: 234-235, 2005.
13. Greenwood T, Vikerfors T, Sjöberg M, Skeppner G and Farnert A: Febrile *Plasmodium falciparum* malaria 4 years after expo-sure in a man with sickle cell disease. *Clin Infect Dis* 47: e39-e41, 2008.
14. Theunissen C, Janssens P, Demulder A, Nouboussie D, Van-Esbroeck M, Van-Gompel A and Van-Denende J: Falciparum malaria in patient 9 years after leaving malaria-endemic area. *Emerg Infect Dis* 15: 115-116, 2009.
15. World Malaria Report-World Health Organization, 2010. <https://www.who.int/publications/i/item/9789241564106>. Accessed September 10, 2023.
16. Calle CL, Mordmüller B and Singh A: Immunosuppression in malaria: Do *Plasmodium falciparum* parasites hijack the host? *Pathogens* 10: 1277, 2021.
17. Marletta S, L'Imperio V, Eccher A, Antonini P, Santonicco N, Girolami I, Dei Tos AP, Sbaraglia M, Pagni F, Brunelli M, *et al*: Artificial intelligence-based tools applied to pathological diagnosis of microbiological diseases. *Pathol Res Pract* 243: 154362, 2023.
18. Jensen AR, Adams Y and Hviid L: Cerebral *Plasmodium falciparum* malaria: The role of PfEMP1 in its pathogenesis and Im-munity, and PfEMP1-based vaccines to prevent it. *Immunol Rev* 293: 230-252, 2020.
19. Marino A, Bivona DA and Bonacci P: Updates in central nervous system malaria: Literature review and considerations. *Curr Opin Infect Dis* 35: 255-261, 2022.
20. Centers for Disease Control and Prevention: Malaria Glossary. <https://www.cdc.gov/malaria/glossary.html>. Accessed September 10, 2023.
21. Cryptic malaria guidance-Travel and Migrant Health Section (TMHS), Health Protection Services, 2011.

22. Uzzan B, Izri A, Durand R, Deniau M, Bouchard O and Perret GY: Serum procalcitonin in uncomplicated falciparum malaria: A preliminary study. *Travel Med Infect Dis* 4: 77-80, 2006.
23. Wright WF and Auwaerter PG: Fever and fever of unknown origin: Review, recent advances, and lingering dogma. *Open Forum Infect Dis* 7: ofaa132, 2020.
24. Nagley L: Probable relapse of malignant tertian malaria after thirteen years. *Lancet* 2: 773, 1945.
25. Walters J: Quiescent malarial parasites. *Br Med J* 1: 1206-1207, 1960.
26. Russell PF, West LS, Manwell RD and Macdonald G: Practical malariology. 2nd edition, Oxford University Press, London, pp750, 1963.
27. Revel MP, Datry A, Saint Raimond A, Lenoir G, Danis M and Gentilini M: *Plasmodium falciparum* malaria after three years in a non-endemic area. *Trans R Soc Trop Med Hyg* 82: 832, 1988.
28. Shah S, Filler S, Causer LM, Rowe AK, Bloland PB, Barber AM, Roberts JM, Desai MR, Parise ME and Steketee RW: Malaria Surveillance-United States, 2002. *MMWR Surveill Summ* 53: 21-34, 2004.
29. Howden BP, Vaddadi G, Manitta J and Grayson ML: Chronic falciparum malaria causing massive splenomegaly 9 years after leaving an endemic area. *Med J Aust* 182: 186-188, 2005.
30. D'Ortenzio E, Godineau N, Fontanet A, Houze S, Bouchaud O, Matheron S and Le Bras J: Prolonged *Plasmodium falciparum* infection in immigrants, Paris. *Emerg Infect Dis* 14: 323-326, 2008.
31. Foca E, Zulli R, Buelli F, De Vecchi M, Regazzoli A and Castelli F: *P. falciparum* malaria recrudescence in a cancer patient. *Infez Med* 17: 33-34, 2009.
32. Szmítzko PE, Kohn ML and Simor AE: *Plasmodium falciparum* malaria occurring 8 years after leaving an endemic area. *Diagn Microbiol Infect Dis* 63: 105-107, 2009.
33. Mali S, Kachur SP and Arguin PM: Malaria Surveillance-United States, 2010. *MMWR Surveill Summ* 61: 1-17, 2012.
34. Cullen KA and Arguin PM; Division of parasitic diseases and malaria, center for global health, centers for disease control and prevention (CDC): Malaria Surveillance-United States, 2011. *MMWR Surveill Summ* 62: 1-17, 2013.
35. Monge-Maillo B, Norman F, Pérez-Molina JA, Díaz-Menéndez M, Rubio JM and López-Vélez R: *Plasmodium falciparum* in asymptomatic immigrants from sub-Saharan Africa, Spain. *Emerg Infect Dis* 18: 356-357, 2012.
36. Berrevoets MA, Sprong T, Meis JF and Dofferhoff AS: *Plasmodium falciparum* malaria recrudescence occurring 2.5 years after leaving an endemic country. *Neth J Med* 71: 426-428, 2013.



Copyright © 2023 Marino et al. This work is licensed under a Creative Commons Attribution 4.0 International (CC BY 4.0) License.